



The Toxic Edge—A Novel Treatment for Refractory Erythema and Flushing of Rosacea

Or Friedman, MD ^{1,2*} Amir Koren, MD,^{3,4} Roni Niv, MD,⁴ Joseph N. Mehrabi, BSc,² and Ofir Artzi, MD ^{3,4}

¹The Plastic Reconstructive Surgery Department, Tel Aviv Sourasky Medical Center, Tel Aviv, Israel

²Sackler Faculty of Medicine, Tel Aviv University, Tel Aviv, Israel

³Department of Dermatology, Tel Aviv Sourasky Medical Center, Tel Aviv, Israel

⁴Dr. Artzi Treatment and Research Center, Tel Aviv, Israel

Purpose: Rosacea is a common, chronic facial skin disease that affects the quality of life. Treatment of facial erythema with intradermal botulinum toxin injection has previously been reported. The primary objective of the study was the safety and efficacy of thermal decomposition of the stratum corneum using a novel non-laser thermomechanical system (Tixel, Novoxel, Israel) to increase skin permeability for Botulinum toxin in the treatment of facial flushing of rosacea.

Methods: A retrospective review of 16 patients aged 23–45 years with Fitzpatrick Skin Types II to IV and facial erythematotelangiectatic rosacea treated by Tixel followed by topical application of 100 U of abobotulinumtoxin. A standardized high-definition digital camera photographed the patients at baseline and 1, 3, and 6 months after the last treatment. Objective and subjective assessments of the patients were done via Mexameter, the Clinicians Erythema Assessment (CEA), and Patients self-assessment (PSA) scores and the dermatology life quality index (DLQI) validated instrument.

Results: The average Mexameter, CEA, and PSA scores at 1, 3, and 6 months were significantly improved compared with baseline (all had a P -value < 0.001). DLQI scores significantly improved with an average score of 18.6 at baseline at 6 months after treatment ($P < 0.001$). Self-rated patient satisfaction was high. There were no motor function side-effects or drooping.

Conclusion: Thermal breakage of the stratum corneum using the device to increase skin permeability for botulinum toxin type A in the treatment of facial flushing of rosacea seems both effective and safe. *Lasers Surg. Med.* © 2018 Wiley Periodicals, Inc.

Key words: botulinum toxin; erythema; flushing; rosacea; drug delivery; percutaneous permeating; fractional skin ablation

INTRODUCTION

Rosacea is a chronic, relapsing inflammatory skin disease [1]. Symptoms include persistent facial erythema, papules, pustules, telangiectasia, and recurrent flushing [1]. The red, pimply facial rash can cause embarrassment, low self-esteem, anxiety, and have a considerable

adverse effect on quality of life [2–4]. The prevalence of rosacea across populations is reported to range from less than 1% to 22% and is characterized by episodes of exacerbation and remission. [5–6]. Symptoms only partially respond to therapy and tend to recur. Frequently prescribed treatments include topical, oral, and light-based therapies [1]. Intradermal botulinum toxin has been investigated as a novel treatment of facial erythema and flushing [7–11]. Botulinum toxin (BTX) blocks the release of the neurotransmitter acetylcholine from peripheral nerves and thus might alter cutaneous vasodilatation [12–13]. Due to its characteristics and high molecular weight, BTX cannot penetrate the highly impermeable stratum corneum while applied to bare skin [14].

Disruption of the outer stratum corneum by mechanical, chemical, or physical approaches increases skin permeability [15–17]. Selective thermal ablation of stratum corneum dramatically increased skin permeability for transdermal drug delivery [18–19]. Above 360°C, transdermal flux increased by many orders of magnitude. [20].

This study aimed to assess the safety and efficacy of a novel non-laser thermal resurfacing system (Tixel, Novoxel, Israel) of increasing skin permeability for botulinum toxin type A in the treatment of patients with resistant facial flushing of rosacea. The system has already been demonstrated to significantly increase the permeability of several topically applied medications [21,22].

METHODS

A retrospective review of 16 patients ages 23–45 years (average 41 years) treated in a single center between January 2017 and March 2018. The standard treatment reviewed consisted of a novel thermomechano-ablative

Conflict of Interest Disclosures: All authors have completed and submitted the ICMJE Form for Disclosure of Potential Conflicts of Interest and none were reported.

*Correspondence to: Dr. Or Friedman, MD, Department of Plastic Reconstructive Surgery, Tel Aviv Sourasky Medical Center, 6 Weizman Street, Tel Aviv, 642906 Israel. E-mail: or.friedman@gmail.com

Accepted 8 September 2018

Published online in Wiley Online Library

(wileyonlinelibrary.com).

DOI 10.1002/lsm.23023

device (Tixel, Novoxel, Israel) followed immediately by topical application of 100 U of abobotulinumtoxin A (Dysport[®], Galderma, France) in 3 ml of bacteriostatic saline assisted by ultrasound impact system (Alma lasers GmbH, Germany). Tixel device settings included: 400°C, at contact intervals of 6–8 ms, 800–1000 protrusion. The Impact (Alma Lasers Ltd., Israel, Impact) setting was 50% energy intensity and 50 Hz acoustic pressure pulse rate for 2 minutes. Post-procedure care included topical Trolamine (Biafine; Genmedix Ltd, France) self-applied 3–4 times a day for 2 days and the use of broad-spectrum sunscreen with a sun protection factor of 50 for 3 months. All patients received two treatment sessions with 1-month interval and were followed up for 6 months after the last treatment to monitor results, recurrence, and adverse effects.

Skin cultures for *Demodex folliculorum* were taken before and at 1 month after treatment. The erythema index (EI) of the forehead, cheeks, nose, and chin was measured and averaged, before treatment and at 1, 3, and 6 months post-treatment, using a model MX18 Mexameter (CK Electronic GmbH, Cologne, Germany). The patients were photographed by a standardized high-definition digital camera (VISIA, Canfield) at baseline and 1, 3, and 6 months after last treatment.

Two independent non-treating investigators assessed the subjects' facial erythema using the Clinicians Erythema Assessment (CEA) score (0 = none, 1 = almost none, 2 = mild, 3 = moderate, and 4 = severe). The patients evaluated their own erythema using the Patients self-assessment (PSA) scores (0 = none, 1 = almost none, 2 = mild, 3 = moderate, and 4 = severe). The non-treating investigators and patients were blinded to the chronological sequence of the photos taken when evaluating them. Also, at 6 months post-treatment, the patients answered the dermatology life quality index (DLQI) questionnaire [23]. Pain perception, adverse effects, and recurrence of lesions were also documented at follow-up visits. The presence and severity of the following side effects were assessed in all subjects on clinical examination and written questionnaire: injection site pain, erythema, edema, muscle weakness, dysphagia, dry mouth, fatigue, headache, eye disorders, musculoskeletal pain, and dysphonia.

Statistical analysis was performed using SPSS software (version 21.0; IBM Corporation, Armonk, NY). The effect of treatment on erythema grade was evaluated using a one-way repeated-measures analysis of variance (ANOVA) and pairwise comparisons. A one-way repeated-measures ANOVA was used to determine whether the mean of subjects' rosacea score, at each time point, differed significantly. Student T-test was used to verify DLQI scores before and after treatment.

Stratum Corneum as a Barrier

In general, topical therapeutics demonstrate poor total absorption and cutaneous bioavailability with only 1–5% being absorbed into the skin. [24] Several physical techniques were developed to perforate the stratum corneum to increase the uptake of topically applied drugs.

Among those techniques were electroporation, iontophoresis, lasers, microdermabrasion, microneedles, pressure, RF, and sonophoresis [15–17]. The most significant challenge in achieving an efficient transdermal drug delivery is to create a passage through the stratum corneum [25] while obtaining the lowest damage possible to the viable epidermis and dermis tissue. Mechanical or thermal damage to the tissue might affect the drug passage to the target cells either due to a mechanical blockage such as tissue coagulation or by an inflammatory healing process in case of mechanical damage [24]. The importance of the water content of the stratum corneum in determining its properties is well documented. Skin water content gradually increases, going from the upper layer of the stratum corneum to the viable epidermis, reaching an almost constant value [26,27]. The mechanical properties of the stratum corneum are profoundly affected by the relative humidity (RH%) within the layer. The breaking strength of the stratum corneum increases from about 10 g at 80–100% RH to 45 g at 0% RH, while the elongation to break decreases from 200% at 100% RH to less than 10% at 0% RH [28].

The Tixel Device

The Tixel (Novoxel, Israel) is a non-laser thermomechanical system which transfers thermal energy to the skin, dehydrates the stratum corneum and superficial epidermis and creates micropores, thus, enhancing drug delivery. The system combines thermal energy with motion. The system consists of a titanium tip heated to 400°C. The tip is moving towards the skin to achieve contact between the heated tip and the treated tissue. The amount of thermal energy delivered to the skin is determined by the pulse dwelling duration or pulse duration (range: 5 to 18 ms). A second system parameter is a protrusion, which is defined as the distance in which the heated tip is moving measured from the edge of the handpiece distance gauge. The protrusion is aimed to acquire better thermal matching between the tip and the tissue without skin perforation (including the stratum corneum), along with the process. In transdermal mode settings, the primary thermal effect is dehydration of stratum corneum with a very limited thermal effect on the viable epidermis and dermis. The stratum corneum becomes brittle consequentially to tip thermal effect




Fig. 1. Tixel handle motion assembly.

TABLE 1. Patient Demographics and clinical data

Patient	Sex	age	Fitzpatrick skin type	Disease duration (Y's)	Rosacea type: 1 = Erythematotelangiectatic type 2 = Papulopustular 3 = Phymatous 4 = Ocular		Previous treatments- 1-topical ABX, 2-oral ABX, 3-Isotretinoin, 4-laser, 5-Phototherapy, 6-Exsision
1	F	23	2	15	1+2		1,2,4
2	F	44	2	10	1+2		1,2,4
3	F	73	3	6	1+2		1,2,3,4
4	F	52	2	10	1+2		1,2,3,4
5	F	27	2	5	1		1,2,4
6	F	41	3	10	1		1,2,4
7	F	45	2	13	1		1,2
8	F	41	3	1	1+2		1,2,3,4
9	F	35	2	5	1		1,2
10	F	44	2	2	1		1,2
11	F	36	2	3	1		1,2,4
12	F	36	3	4	1		1,2
13	F	26	4	3	1		1,2,4
14	F	37	2	10	1+2		1,2,3,4
15	F	62	3	10	1		1,2,4
16	F	42	3	12	1		1,2,3,4

leading to layer breakage when the tip is progressed towards the treated tissue. The gentle elimination of the stratum corneum [20] and desiccation of the epidermis establishes a concentration gradient by Fick's law, enhancing drug delivery. The Tixel technology is mainly concentrated in the system handle. Figure 1 presents the general assembly of the handle. The tip motion is achieved by linear motor and motion controller. When the system is activated the linear motor (that act like pneumatic piston energized by electric power) shaft is moving forward and allows the tip to come in contact with the tissue for extremely short period of time. Since the motion controller is located extremely closed to the motor there are no time delays, that is, phase shift therefore the system maintains extremely tight control characteristics. It has been previously shown to enhance the delivery of several medications (e.g., verapamil, vitamin C, and sodium diclofenac) [29].

The Impact Device

Sonophoresis—the use of ultrasound to enhance the transport of a substance through a liquid medium—is particularly impressive given the emerging role of ultrasound in dermatology. A transdermal sonophoresis delivery system (Alma Lasers Ltd.) has been developed to enhance the delivery of topical cosmeceuticals. The device operates at low ultrasound frequency (~30 kHz) and emits acoustic wave air pressure from an ultrasonic horn applied on the skin surface. This horn device has a frequency up to 100 Hz (acoustic pulse vibration per second) and energy of peak of 0.4 W/cm^2 . The hypothesis is that the device

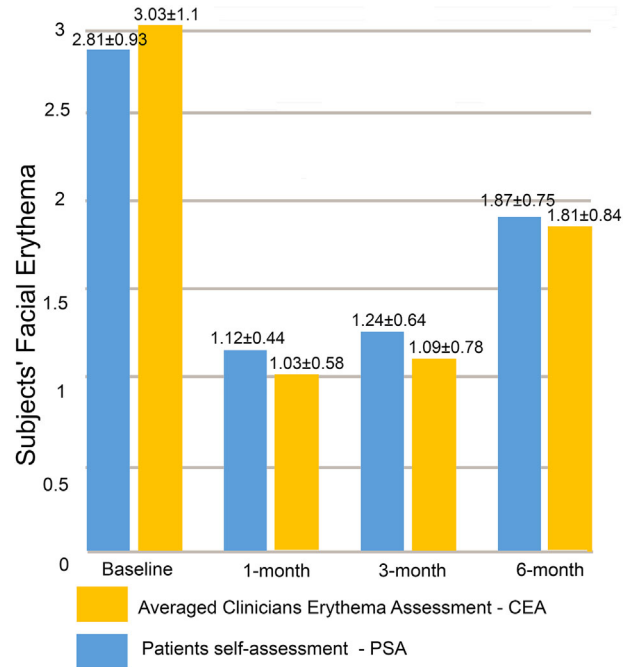


Fig. 2. Clinicians Erythema Assessment (CEA) score and Patient self-assessment (PSA) score – baseline, 0 = none, 1 = almost none, 2 = mild, 3 = moderate, and 4 = severe. The average CEA at 1, 3, and 6 months were significantly improved compared with baseline (all had P -value < 0.001). Note that the greatest effect appeared 1 month after treatment with a slight gradual recurrence of the redness at 3 and 6 months, but none returned to the initial baseline values.

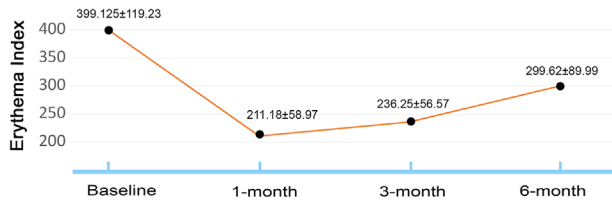


Fig. 3. Average Mexameter scores—baseline, 1, 3, and 6 months (P -value <0.001).

mechanical ultrasound wave/vibration pushes active components deeper into the skin and enhances topical absorption when paired with the thermomechanical stratum corneum destruction produced by the Tixel [30].

RESULTS

Age, Fitzpatrick skin type, previous treatments, and rosacea type are elaborated in Table 1. Positive *Demodex folliculorum* cultures were significantly reduced from nine patients before treatment to four patients after treatment. The CEA results from the two blinded dermatologists showed a strong correlation with a correlation coefficient of 0.9. The average CEA and PSA scores at 1, 3, and 6 months were significantly improved compared with baseline (all had a P -value <0.001, Fig. 2). The average Mexameter scores at baseline, 1, 3, and 6 months were 399.12, 211.18, 236.25, and 299.62 (P -value <0.001, Fig. 3), respectively. Note that the greatest effect appeared 1 month after treatment with a slight gradual recurrence of the redness at 3 and 6 months, but none returned to the initial baseline values (Fig. 4). DLQI Scores were significantly improved with an average score of 18.6 ± 1.9 at baseline and 9.6 ± 2.8 at 6 months after treatment ($P < 0.001$). Patient satisfaction was 2.3 ± 0.5 (on a scale of 0–4). Overall tolerance score was high (average: 3.2 ± 0.3 , scale 1–4). Post-treatment side effects included transient erythema, edema, mild discomfort, and pinpointed micro crusts. All adverse effects were self-limited. Specifically, there were no subjects that developed motor function deficits or drooping.

DISCUSSION AND CONCLUSIONS

Rosacea is a chronic and recurrent inflammatory skin disease with a variety of cutaneous manifestations [1]. It consists of four subtypes: erythematotelangiectatic, papulopustular, phymatous, and ocular [8]. The disorder poses significant financial, physical, and psychological impacts [2–4]. There are some topical, oral, systemic, and energy-based device treatments available, but the treatment of rosacea remains difficult. The multifactorial nature of the disease combined with an incomplete understanding of the pathophysiology is challenging for providers and patients. Genetic factors, dysregulation of the innate and adaptive immune system, vascular and neuronal dysfunction, and microorganisms such as *Demodex folliculorum* appear to be involved [31–36].

Micro dermal injections of BTX have been shown to be effective in decreasing flushing, erythema, and inflammation within 1 week of treatment and persisting for up to 3

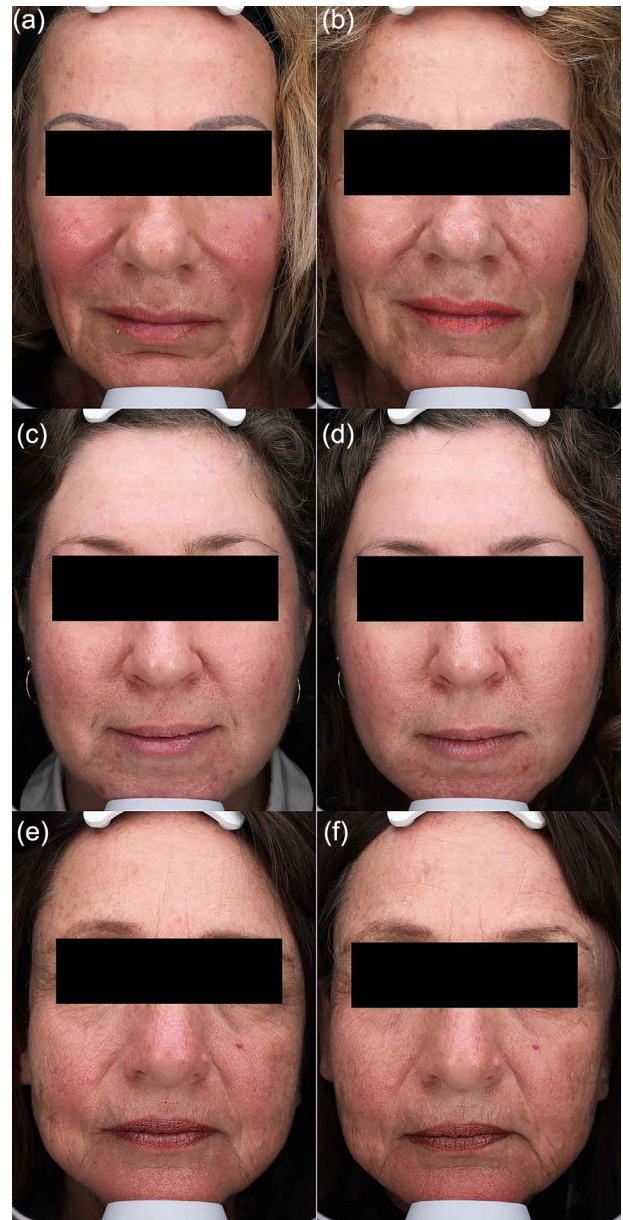

Fig. 4. Representative rosacea status before (a,c,e) and 6 months after (b,d,f) treatment.

months [37–40]. BTX inhibits the exocytosis of preformed vesicles in cholinergic nerves (motor and autonomic) and results in the blockade of acetylcholine release [1]. One possible mechanism by which botulinum toxin might improve flushing is through the blockade of acetylcholine release from peripheral autonomic nerves of the cutaneous vasodilatory system. Other mechanisms might include the followings: BTX inhibits the release of other neurotransmitters (substance P, glutamate, and calcitonin gene-related peptide) or diminishes non-nociceptive stimuli, altering postganglionic cholinergic nerve fibers with blood vessels [41–45]. Due to its characteristics and high molecular weight, the botulinum toxin molecules cannot

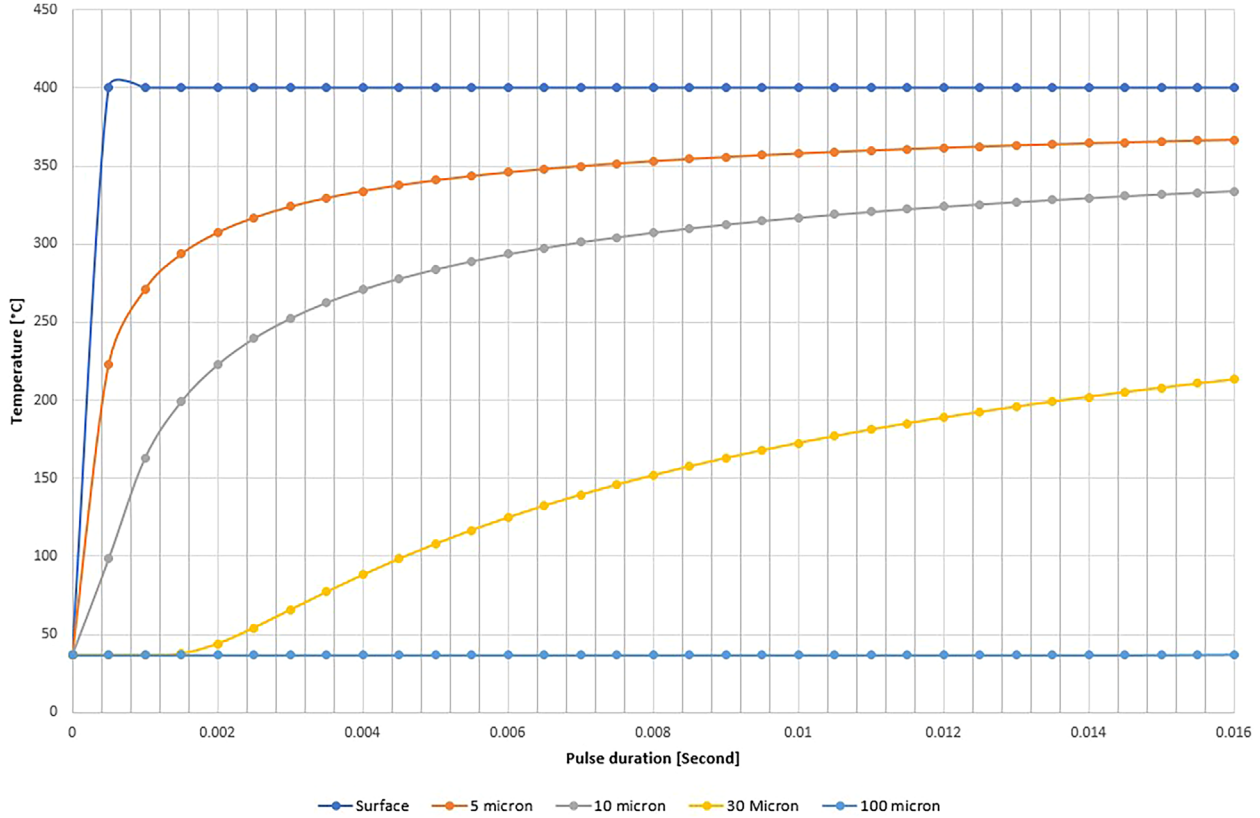


Fig. 5. Chart representing temperature as a function of depth. For example at 10 μm the maximal calculated temperature at pulse duration of 6 ms is 300°C and at 30 μm the maximal temperature is about 125°C.

penetrate the highly impermeable stratum corneum while applied to bare skin, unless disrupted [14].

Topical delivery of drugs is essential in dermatology. The efficacy of topical therapy is dependent on the ability of the therapeutic drug to reach its target. However, cutaneous biodistribution and bioavailability of most topically applied drugs are quite low. For a topical agent to be active, it must first traverse the rate-limiting barrier of the stratum corneum. In the last decades, drug delivery technology has advanced from unsophisticated and simple methods to more advanced chemical, mechanical and physical methods. The main skin permeation enhancement techniques include alteration of drug or vehicle interaction, the use of transepidermal carriers, the modification (e.g., hydration) or removal (microneedling, laser-assisted delivery [LAD]) of stratum corneum or the use of electrically assisted methods (sonophoresis or iontophoresis, transfollicular positive-pressure delivery). A good transepidermal delivery system is based on achieving a suitable balance between effective delivery, homogenous distribution, safety to the skin, and low pain and cost. As examples, tape stripping is a simple, efficient, and controllable method to remove stratum corneum, however it is associated with high incidence of irritation and difficulty in recovering. On the other side, laser-assisted delivery (LAD) can directly adjust the character of the channels in a

predictable and controllable manner, however, these system are expensive to use, relatively painful and sometimes are not cost effective. The Tixel is a relatively inexpensive, very safe, efficient (no down time), non-painful system which allows effective delivery and homogenous distribution of topically applied medications. There are few different aspects of system operation that can provide explanation for the low pain level during Tixel treatment at low pulse duration. Due to the direct conduction in which the Tixel technology is based, the temperature below the stratum corneum (under 20 μm) is much lower than 400°C as shown in the Figure 5. For example, at 10 μm the maximal calculated temperature at pulse duration of 6 ms is 300°C and at 30 μm the maximal temperature is about 125°C. Nociceptors are located deeper at 50 μm [46]. In addition, nociceptors are extremely sensitive to temperature changes rate over time. CO₂ lasers, for example, generate heat at an extremely fast pathway (~ 200 ns), while Tixel heating effect is slower by at least one order of magnitude in the Tixel system [47].

This study demonstrates the successful and safe treatment of resistant rosacea-associated facial erythema using a dual modality treatment of thermal decomposition of the stratum corneum followed by the immediate application of botulinum toxin. No significant adverse

effects were reported with this approach. The authors do appreciate the considerable expense of the botulinum toxin needed for this treatment and the fact that in most countries the treatment would not be covered by insurance.

Limitations of this study include the small sample size, the short 6 month follow up period, and the lack of a control group. The use of botulinum toxin is a rational approach if one assumes that neuron-mediated vascular dysfunction plays essential pathogenic roles in rosacea [31,32]. The use of multiple modalities: thermomechanical device, botulinum toxin, ultrasound device, and Biafine limit our ability directly describe the mechanism of action leading to our observations. Each modality has been chosen based on its published literature and the end result seems greater than the expected additive effect.

However, this study raises many questions: What is the role of the Tixel device? Is it only a drug delivery enhancing system? Does the heat transfer affect the papillary dermal blood vessels or decrease the number of parasites (*Demodex folliculorum*)? What is the role of sonophoresis? Could the same effect be achieved without the concomitant use of the Impact device? Could the same results can be achieved with only topical application of BTX and sonophoresis? All of these questions more substantial, randomized, blinded, and placebo-controlled studies. Additionally, further investigation is needed to elucidate the mechanism of action by which botulinum toxin improves facial flushing of rosacea.

References

1. van Zuuren EJ, Fedorowicz Z, Carter B, van der Linden MM, Charland L. Interventions for rosacea. *Cochrane Database Syst Rev* 2015;4:CD003262.
2. Halioua B, Cribier B, Frey M, Tan J. Feelings of stigmatization in patients with rosacea. *J Eur Acad Dermatol Venereol* 2017;31:163–168.
3. Bewley A, Fowler J, Schöfer H, Kerrouche N, Rives V. Erythema of rosacea impairs quality of life: Results of a meta-analysis. *Dermatol Ther (Heidelb)* 2016;6:237–247.
4. Egeberg A, Hansen PR, Gislason GH, Thyssen JP. Patients with rosacea have increased risk of depression and anxiety disorders: A Danish nationwide cohort study. *Dermatology* 2016;232(2):208–213.
5. Elewski BE, Draelos Z, Dréno B, Jan-sen T, Layton A, Picardo M. Rosacea—Global diversity and optimized outcome: Proposed international consensus from the Rosacea International Expert Group. *J Eur Acad Dermatol Venereol* 2011;25:188–200.
6. Tan J, Berg M. Rosacea: Current state of epidemiology. *J Am Acad Dermatol* 2013;69(Suppl 1):S27–S35.
7. Alexandroff AB, Sinclair SA, Langtry JA. Successful use of botulinum toxin a for the treatment of neck and anterior chest wall flushing. *Dermatol Surg* 2006;32:1536.
8. Bansal C, Omlin KJ, Hayes CM, Rohrer TE. Novel cutaneous uses for botulinum toxin type A. *J Cosmet Dermatol* 2006; 5:268–272.
9. Sterodimas A, Nicolaou M, Paes TR. Successful use of Botulinum toxin-A for the treatment of neck and anterior chest wall flushing. *Clin Exp Dermatol* 2003;28:592–594.
10. Tugnoli V, Marchese Ragona R, Eleopra R, et al. The role of gustatory flushing in Frey's syndrome and its treatment with botulinum toxin type A. *Clin Auton Res* 2002;12:174–178.
11. Yuraitis M, Jacob CI. Botulinum toxin for the treatment of facial flushing. *Dermatol Surg* 2004;30:102–104.
12. Charkoudian N. Skin blood flow in adult human thermoregulation: How it works, when it does not, and why. *Mayo Clin Proc* 2003;78:603–612.
13. Kellogg DL Jr. *In vivo* mechanisms of cutaneous vasodilation and vasoconstriction in humans during thermoregulatory challenges. *J Appl Phys* 2006;100:1709–1718.
14. Egawa M, Hirao T, Takahashi M. *In vivo* estimation of stratum corneum thickness from water concentration profiles obtained with raman spectroscopy. *Acta Derm Venereol* 2007;87:4–8.
15. Gratieri T, Alberti I, Lapteva M, Kalia YN. Next generation intra- and transdermal therapeutic systems: Using non- and minimally-invasive technologies to increase drug delivery into and across the skin. *Eur J Pharm Sci* 2013;50(5):609–622.
16. Sklar LR, Burnett CT, Waibel JS, Moy RL, Ozog DM. Laser assisted drug delivery: A review of an evolving technology. *Lasers Surg Med* 2014(46):249–262.
17. Paudel KS, Milewski M, Swadley CL, Brogden NK, Ghosh P, Stinchcomb AL. Challenges and opportunities in dermal/transdermal delivery. *Ther Deliv* 2010;1(1):109–131.
18. Park JH, Lee JW, Kim YC, Prausnitz MR. The effect of heat on skin permeability. *Int J Pharm* 2008;359(1-2):94–103.
19. Lee JW, Gadiraju P, Park JH, Allen MG, Prausnitz MR. Microsecond thermal ablation of skin for transdermal drug delivery. *J Control Release* 2011;54(1):58–68.
20. Lask G, Elman M, Fournier N, Slatkine M. Fractional vaporization of tissue with an oscillatory array of high temperature rods—Part I: *Ex vivo* study. *J Cosmetic and Laser therapy* 2012;5:218–223.
21. Elman M, Fournier N, Barneon G, Hofmann M, Bernstein MD, Lask G. Fractional treatment of aging skin with tixel, a clinical and histological evaluation. *J Cosm Therap* 2015;18(1):31–37.
22. Sintov AC, Brandys -, Sittin R. Facilitated skin penetration of lidocaine: Combination of a short-term iontophoresis and microemulsion formulation. *Int J Pharma* 2006;316:58–67.
23. Finlay AY, Khan G. Dermatology Life Quality Index (DLQI): A simple practical measure for routine clinical use. *Clin Exp Dermatol* 1994;19:210–216.
24. Erleendsson AM, Wenande E, Haedersdal M. Transepidermal drug delivery: Overview, Concept, and Applications. In: Issa M, Tamura B, editors. *Lasers, lights and other technologies. Clinical Approaches and Procedures in Cosmetic Dermatology*. Springer, Cham. 2018. pp 447–461.
25. Uchida Y, Park K. Stratum Corneum. In: Kabashima K, editor. *Immunology of the skin*. Tokyo: Springer; 2016. pp 15–30.
26. Warner RR, Myers MC, Taylor DA. Electron probe analysis of human skin: Determination of the water concentration profile. *J Invest Dermatol* 1988;90:218–224.
27. Stockdate M. Water diffusion coefficients versus water activity in Stratum Corneum: A correlation and its implications. *J Soc Cosmetic Chemists* 1978;29:625–639.
28. Wildnauer RH, Bothwell JW, Douglass AB. Stratum corneum biomechanical properties I. Influence of relative humidity on normal and extracted human stratum corneum. *J Investig Dermatol* 1971;56(1):72–78.
29. Sintov AC, Hofmann MA. A novel thermomechanical system enhanced transdermal delivery of hydrophilic active agents by fractional ablation. *Int J Pharm* 2016;511(2):821–830.
30. Waibel JS, Rudnick A, Nousari C, Bhanusali DG. Fractional ablative laser followed by transdermal acoustic pressure wave device to enhance the drug delivery of aminolevulinic acid: *In Vivo* fluorescence microscopy study. *J Drugs Dermatol* 2016;15(1):14–21.
31. Gomaa AH, Yaar M, Eyada MM, Bhawan J. Lymphangiogenesis and angiogenesis in non-phymatous rosacea. *J Cutan Pathol* 2007;34:748–753.
32. Guzman-Sanchez DA, Ishiuiji Y, Patel T, et al. Enhanced skin blood flow and sensitivity to noxious heat stimuli in papulopustular rosacea. *J Am Acad Dermatol* 2007;57:800–805.
33. Schwab VD, Sulk M, Seeliger S, Nowak P, et al. Neurovascular and neuroimmune aspects in the pathophysiology of rosacea. *J Investig Dermatol Symp Proc* 2011;15: 53–62.
34. Sibenge S, Gawkrödger DJ. Rosacea: A study of clinical patterns, blood flow, and the role of *Demodex folliculorum*. *J Am Acad Dermatol* 1992;26:590–593.

35. Bernstein EF, Schomacker K, Paranjape A, Jones CJ. Pulsed dye laser treatment of rosacea using a novel 15 mm diameter treatment beam. *Lasers Surg Med* 2018;50(8):808–812.
36. Stephens DP, Saad AR, Bennett LA, et al. Neuropeptide Y antagonism reduces reflex cutaneous vasoconstriction in humans. *Am J Physiol Heart Circ Physiol* 2004;287: H1404–H1409.
37. Dayan SH, Pritzker RN, Arkins JP. A new treatment regimen for rosacea: OnabotulinumtoxinA. *J Drugs Dermatol* 2012;11-(12):e76–e79.
38. Park KY, Hyun MY, Jeong SY, Kim BJ, Kim MN, Hong CK. Botulinum toxin for the treatment of refractory erythema and flushing of rosacea. *Dermatology* 2015;230(4): 299–301.
39. Schlessinger J, Gilbert E, Cohen JL, Kaufman J. New uses of abobotulinumtoxinA in aesthetics. *Aesthet Surg J* 2017;37-(suppl_1):S45–S58.
40. Bloom BS, Payongayong L, Mourin A, Goldberg DJ. Impact of intradermal abobotulinumtoxinA on facial erythema of rosacea. *Dermatol Surg* 2015;41(Suppl 1):S9–16.
41. Guo BL, Zheng CX, Sui BD, Li YQ, Wang YY, Yang YL. A closer look to botulinum neurotoxin type A-induced analgesia. *Toxicon* 2013;71:134–139.
42. Pickett A. Re-engineering clostridial neurotoxins for the treatment of chronic pain: Current status and future prospects. *BioDrugs* 2010;24(3):173–182.
43. Patil S, Willett O, Thompkins T, et al. Botulinum toxin: Pharmacology and therapeutic roles in pain states. *Curr Pain Headache Rep* 2016;20(3):15.
44. Ney JP, Joseph KR. Neurologic uses of botulinum neuro-toxin type A. *Neuropsychiatr Dis Treat* 2007;3(6):785–798.
45. Purkiss J, Welch M, Doward S, Foster K. Capsaicin-stimulated release of substance P from cultured dorsal root ganglion neurons: Involvement of two distinct mechanisms. *Biochem Pharmacol* 2000;59(11):1403–1406.
46. Zhu YJ, Lu TJ. A multi-scale view of skin thermal pain: From nociception to pain sensation. *Phil Trans R Soc A* 2010; 368:521–559.
47. Harris M, Fried D, Reinisch L, et al. Eyelid resurfacing. *Lasers Surg Med* 1999;25:107–122.